HOW TO

# PREPARE BIRD SPECIMENS

Part 13 – Determining cause of death

- Part 13A – Poisons
- Part 13B – What is wildlife forensic pathology & Fishing, hunting, and trauma wound analysis
- Part 13C – Collision with man-made structures
- Part 13D – Diseases & Ectoparasites


The Migratory Bird Conventions Act regulates the take and possession of birds in Canada. The Migratory Bird Treaty Act regulates the take and possession of birds in the United States. In addition, the provinces (in Canada) and the states (in the United States) also require permits. For some species SARA, ESA, or CITES permits may be required.

Check the laws of your country and obtain the proper permits; failure to do so may result in civil and/or criminal penalties.

When handling dead birds, it is probably impossible to tell if a bird is infected with a pathogen that may cause human illness even if you know the cause of death to be a wound or an injury. Take reasonable precautions to protect yourself. The Ornithological Council offers a peer-reviewed fact sheet on avian zoonotic disease and safety precautions for those who handle birds in the field and in the lab.

http://www.nmnh.si.edu/BIRDNET/documents/WNV&H5N1-FactSheet.pdf

# Report All Suspected Poisonings to the Proper Authorities

**Reviewing this PowerPoint does not replace the need to consult a certified avian pathologist.**

•In many museums, the majority of new museum specimens are salvaged birds. This presentation will aid novice preparators to more accurately identify and record cause of death.

•It is hoped that this cell phone accessible reference will aid individuals who find dead birds to better describe what they have found. It is stressed that dead wildlife and related evidence must not be compromised before wildlife enforcement personal arrive. Poisons are dealt with first because many are equally lethal to humans.

Take a reference photograph containing a landmark. Something that is visually incontrovertible.


Photo courtesy of Science and advice for Scottish Agriculture


Photo courtesy of Iñigo Fajardo

A minor error in recording GPS coordinates can lead to a case being dismissed.

A reference tree, building, etc. is unlikely to move!

Window collision is the leading cause of anthropogenic bird mortality.
A broken neck is practically never the manner of death.


Look for:

- Severed arteries
- Stretched trachea near clavicle bones
- Broken clavicle bones
- Subdural haemorrhage (blood in the outer brain lining)
- Liver contusions (lacerations)

Stunned birds with no internal injuries die from:

Predation:
•Stunned birds are extremely venerable.

Beak damage:
• Bird dies of starvation.

*Photo courtesy of P Plant, S Scarf,*
*Fatal Light Awareness Program - FLAP.org*

Check the glass above a window collision. Some bird species have a talcum powder-like preening aid produced by powder down feathers.

A Rock Pigeon left this dust print. Owls, pigeons, and several other bird families leave dust prints.

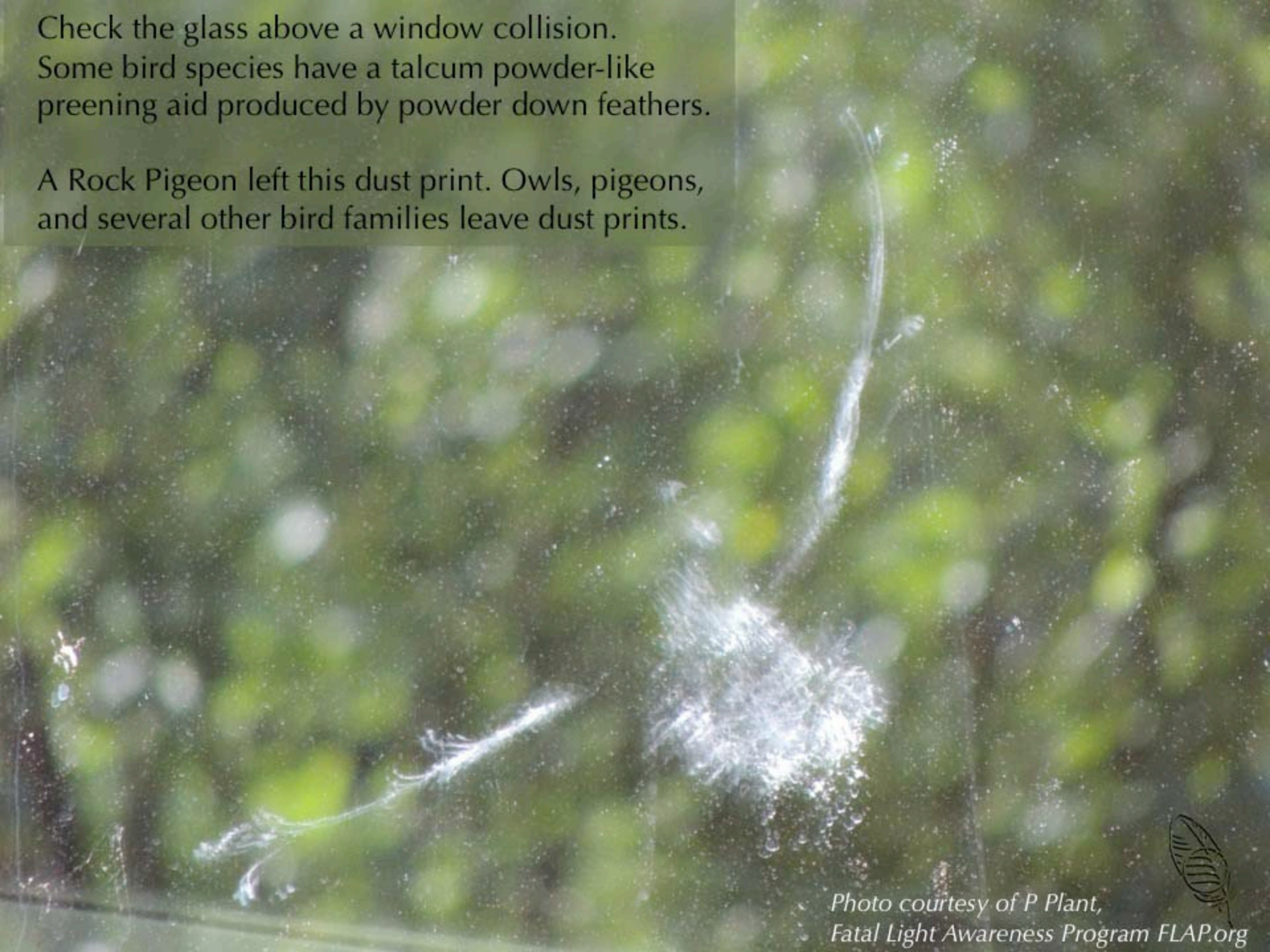

*Photo courtesy of P Plant, Fatal Light Awareness Program FLAP.org*

Flying through a methane flare at a landfill singed the left wing of this Red-tailed Hawk.

*Photo courtesy of Joey Mason, Keeping Company with Kestrels*

*Image: Rick Harness*

**Photo 16. Large external stack burner.**

*Image: Rick Harness*

**Photo 17. Medium intermittent candlestick burner.**

*Image: Rick Harness*

**Photo 18. Multiple intermittent burners.**

Methane flares burn unwanted gases at landfills.

Oil producers use flares to remove unwanted gas stranded in pipelines.

Raptors use inactive structures as roosting and hunting perches. They are incinerated or singed when the flare is activated by gas pressure build-up or other triggers.

*Image: Joey Mason*

**Photo 19. Enclosed burner.**

*Image: Joey Mason*

**Photo 20. Intermittent solar flare.**

*Image: Joey Mason*

**Photo 21. Intermittent solar flare.**

*Photos from: Methane Burner Impacts on Raptors, 2013. Keeping Company with Kestrels & EDM International, Inc*

*Image: Rocky Mountain Raptor Program*

**Photo 13. Swainson's Hawk tail feather burns due to a flared vessel.**

*Image: Rocky Mountain Raptor Program*

**Photo 15. Burned beak.**

*Image: Rocky Mountain Raptor Program*

**Photo 14. Burned foot.**

Note the external nature of the burns on the feathers, head, and feet. For additional info:

http://www.keepingcompanywithkestrels.org/wp-content/uploads/2012/01/Methane-Burner-Impacts-on-Raptors.pdf

*Photos from: Methane Burner Impacts on Raptors, 2013. Keeping Company with Kestrels and EDM International, Inc*

Look carefully at damaged feathers to determine if they are due to:

- Methane flare (upper wing coverts depicted above)
- Ectoparasite feasting
- Electrocution

Medium-heavy feather lice infestation frayed these upper wing coverts.


Electrocuted Bald Eagle upper leg feathers


Why is this
electrocution?
Photo courtesy
of
Mark Conway

# … and this is not?

Not all birds killed on utility structures are electrocutions.

Demoiselle Crane

*Photo courtesy of Rick Harness*
*EDM International, Inc*

Birds perch regularly on electrical wires, power poles, and pylons with no ill effects.

Electrocution occurs when a bird completes a circuit between
two different live phase wires,
or between a live phase wire and a ground (insulator, utility pole, etc.)

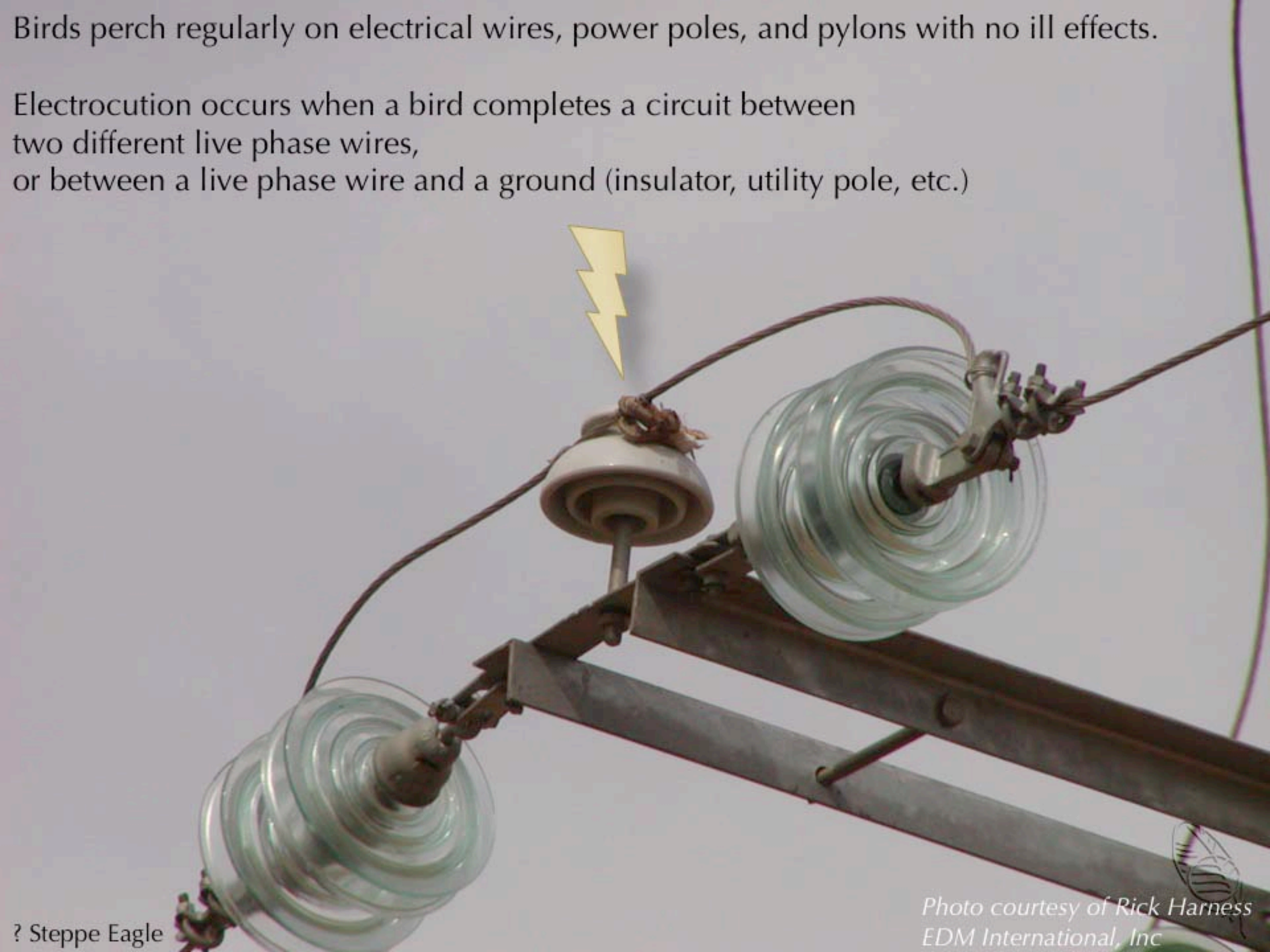

? Steppe Eagle

*Photo courtesy of Rick Harness*
*EDM International, Inc*

Check the feet.
It is easy to tell which foot of this juvenile Bald Eagle completed part of an electrical circuit.

If you see external foot discolouration,
search for a “pinhole” exit wound.

Also check internal discolouration
(the smell is reminiscent of chicken soup).

Two photos of the same foot.

This Bald Eagle’s muscles are cooked !

If the electrical shock causes acute heart fibrillations, heart stoppage, or brain damage, death occurs instantly.

We think of electricity as passing through a body in a straight line.

This is rarely the case.

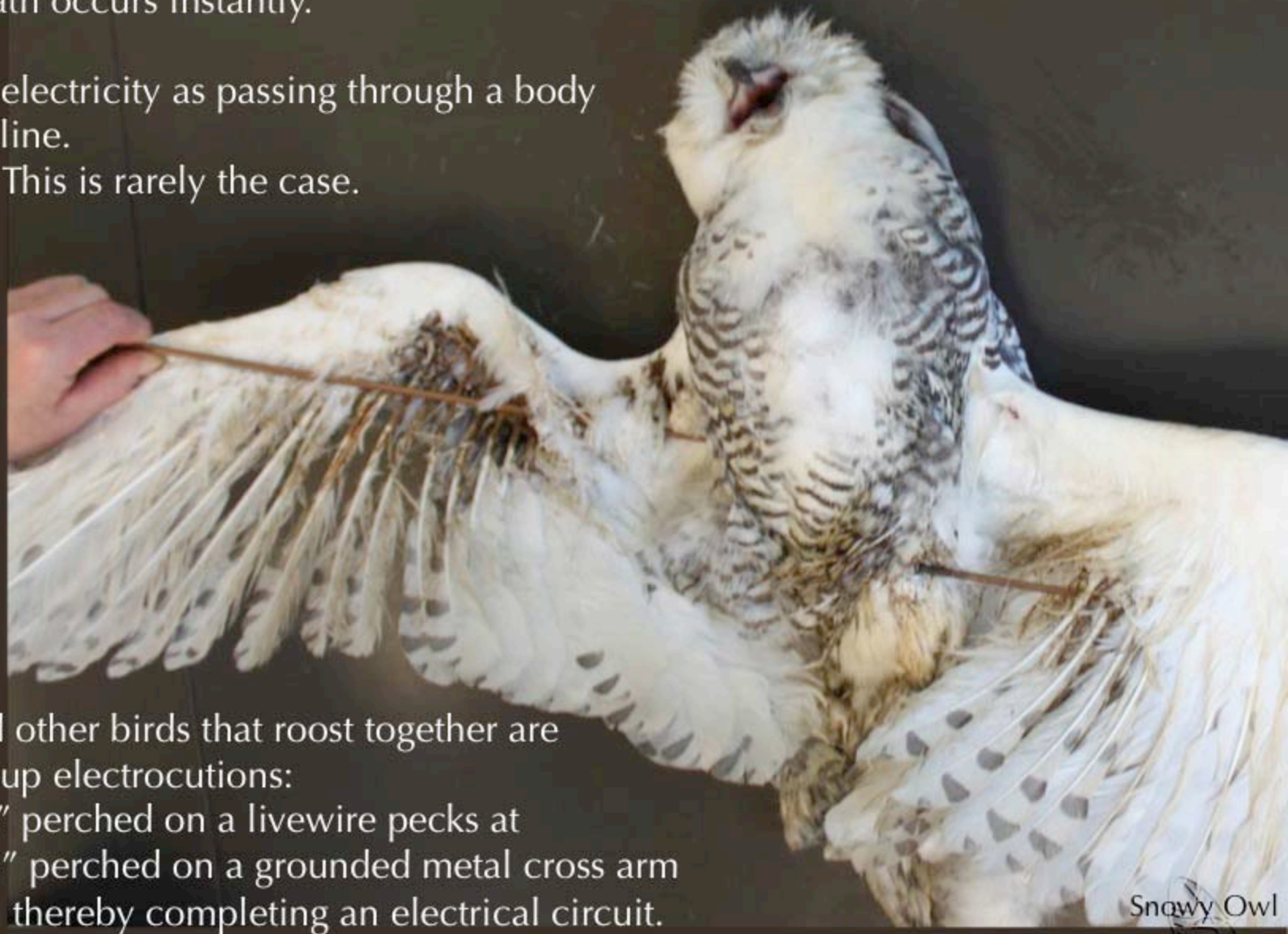


Vultures and other birds that roost together are prone to group electrocutions:

e.g.) Bird "A" perched on a livewire pecks at
Bird "B" perched on a grounded metal cross arm
- thereby completing an electrical circuit.
Birds "C… Z" touching birds "A or B" join the electrical circuit web.
Some birds may die, others experience a mild electrical shock.

Prey items "increase" the size of the bird – check prey for electrocution.
The snake has an exit hole and the duck's wing feathers are singed.

*Photo from: Guide to Raptor Remains, 2004. EDM International, Inc*


Inspect wings, wrists, and wing pit regions for charred feathers. Check the rest of the plumage. It may smell burnt.
This is a classical electrical entrance wound. It is not usually this obvious.
Bald Eagle
Photo courtesy of Dr. Victoria Bowes

Electricity entered the leg of this swan and exited through the breast.

Note the subtle charring on the internal and external edges of the exit burn hole.

Trumpeter Swan

Electrical scorching is easiest to see on white feathers. Exam the inside of the skin for entrance and exit holes. These pictures are of the same lower leg area.

Symptoms of lightning electrocution:

Usually effects flying flocks rather than single individuals:

- Ruptured tympanic membranes
- Blunt trauma from falling out of the sky and landing on the ground, trees, roofs, etc.
- Subtle to absent gross changes
- Mass mortalities

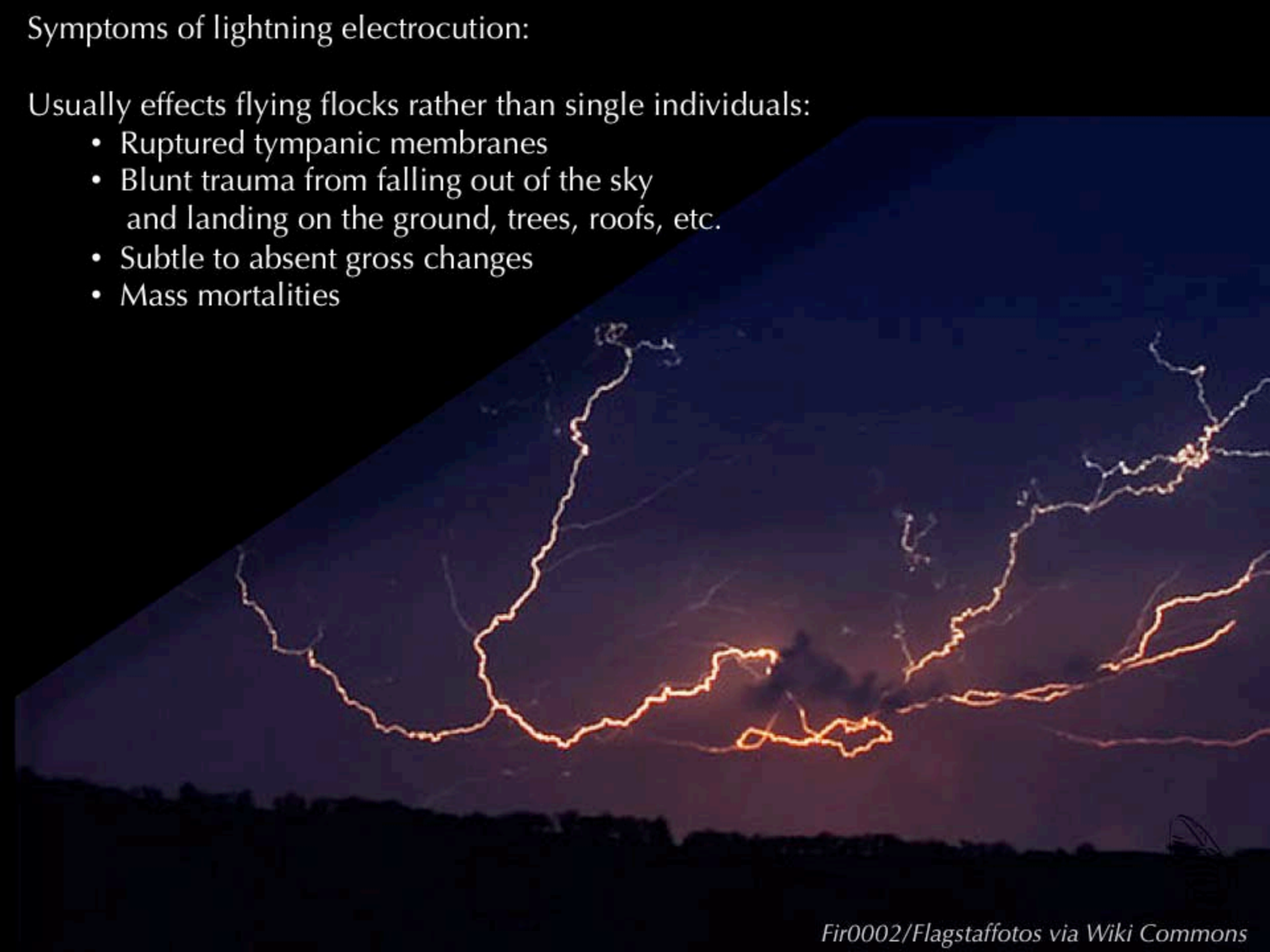

*Fir0002/Flagstaffotos via Wiki Commons*

*Leaflet via Wikimedia Commons*

Bird casualties from land-based wind turbines are likely to be found. Stunned birds have a greater chance of survival. Check birds for blunt trauma. Scavengers could relocate bird remains.

*Hans Hillewaert via Wikimedia Commons*

Ocean-based wind turbine bird casualties sink or drift with the tides. Stunned birds are apt to drown. Check beached birds for blunt trauma and/or drowned lungs.

AN OILED BIRD IS EVIDENCE! Remember to PHOTOGRAPH everything.

What to look for:

- Oil soiled feathers
- Encasement
- Ingestion
- Inhalation

Mechanisms of death:

- Mechanical disruption of feathers
- Chemical burns (eyes, skin,
- mouth lining, nasal cavities)
- Respiratory system damage due to inhalation of fumes
- Inability to feed
- Immune system depression
- Locomotion inhibition

*Photo courtesy of Dr. Pepper Trail*
*US National Fish & Wildlife Forensic Lab*

Manner of death can be hypothermia, dehydration, starvation, organ failure, secondary infection, stress, exhaustion,

… or drowning.

*Photo courtesy of Oiled Wildlife Society*

Oiling changes how air is trapped between feathers and the skin thereby decreasing insulation, waterproofing, and buoyancy.

Oil ingested while preening may result in kidney, liver, or other internal organ failure. A necropsy might reveal oil in the stomach, ulcers, or internal bleeding.

*Photo courtesy of Oiled Wildlife Society*

Take photographs of the bird before it is cleaned and with the data clearly visible. A white board simplifies this procedure.

*Photo courtesy of International Bird Rescue*

Include the following:

- Spill name
- Intake log number
- Date and time
- Species
- Band number

Take close-ups of affected areas. For chain-of-custody reasons, camera memory chips must be stored in a locked safe.

Do not alter or rename the photos (see Part 13B).

# To link oiled wildlife to the contamination source, collect for analysis:

1: Oiled birds

If the bird is alive, pluck a few oiled body feathers by pulling them in the direction of feather growth BEFORE the bird is cleaned.


*Sampling photos courtesy of International Bird Rescue*

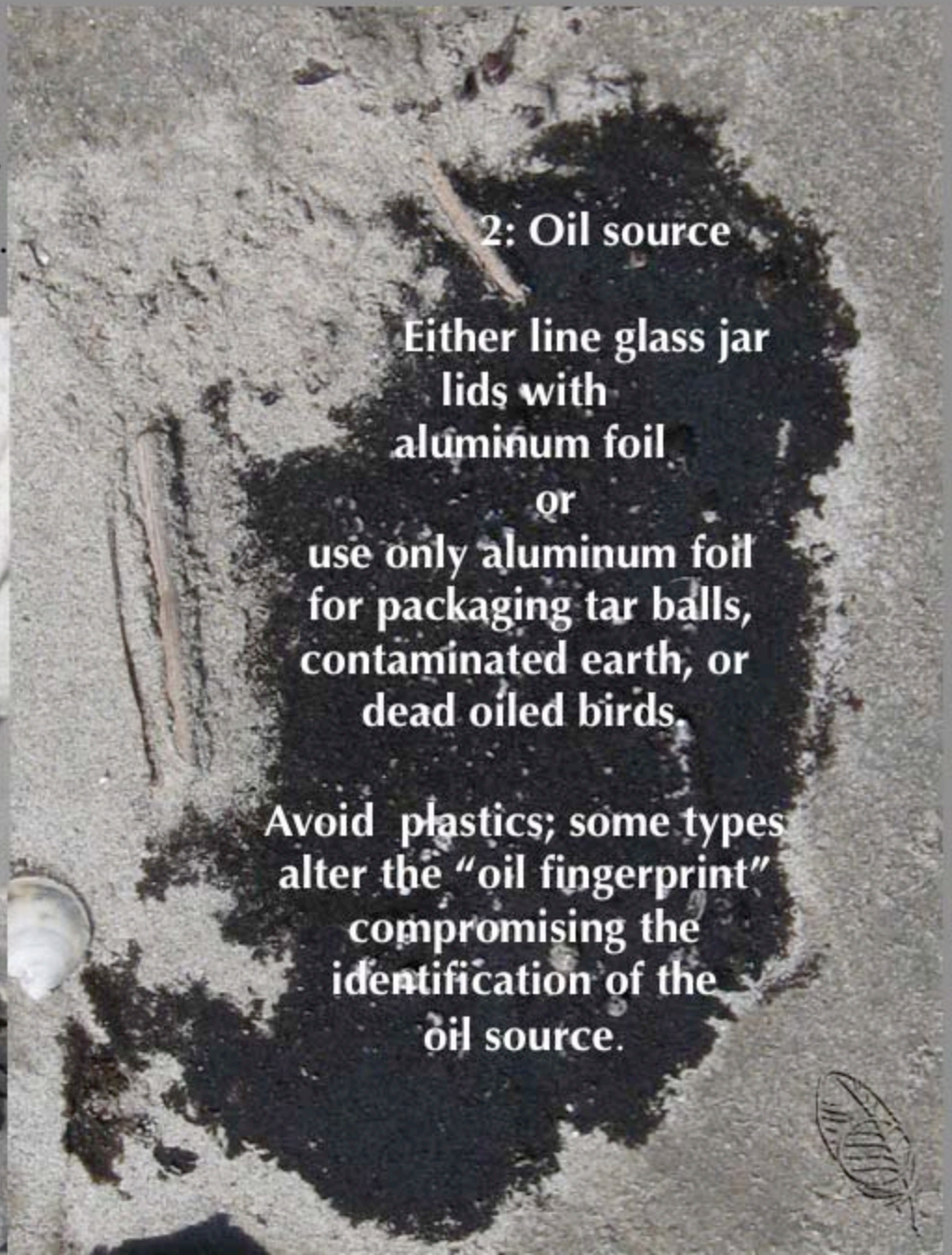

**2: Oil source**

**Either line glass jar lids with aluminum foil or use only aluminum foil for packaging tar balls, contaminated earth, or dead oiled birds.**

**Avoid plastics; some types alter the "oil fingerprint" compromising the identification of the oil source.**

Not all oiled birds are from major marine oil spills. Check petroleum production facilities and industrial areas in the region.

Types of Crude Oil

Class A:

- Light, volatile
- Not very adherent
- Causes burns
- Lung damage
- Neurologic damage

Class B:

- Non-sticky oils, paraffin based
- Usually do not affect birds

Class C:

- Heavy, sticky oils
- Feather damage
- Can encrust birds

Class D:

- Non-fluid

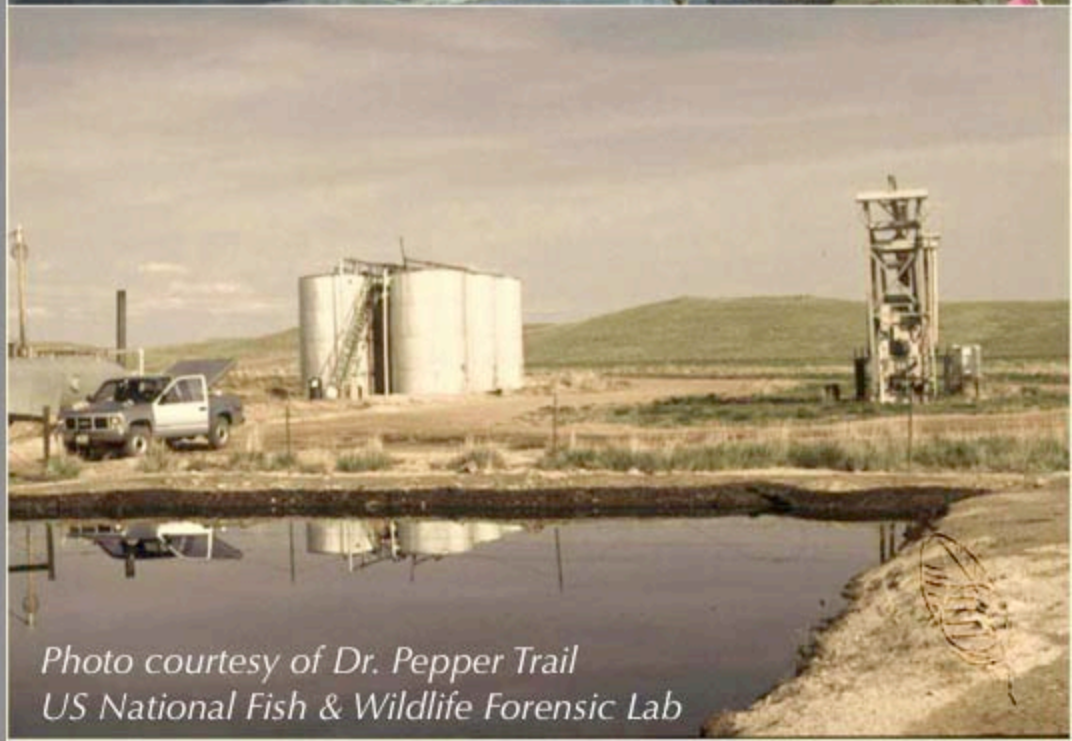

*Photo courtesy of Dr. Pepper Trail*
*US National Fish & Wildlife Forensic Lab*

# HOW TO PREPARE BIRD SPECIMENS

Part 13 – Determining cause of death

Part A – Poisons
Part B – What is wildlife forensic pathology & Fishing, hunting, and trauma wound analysis
Part C – Collision with man-made structures
Part D – Diseases & Ectoparasites

This Northwestern Crow has avian dry pox.

*Photo courtesy of* Dr. Helen Schwantje

The Ornithological Council has a peer-reviewed fact sheet on avian zoonotic disease and safety precautions for those who handle birds in the field and in the lab.

http://www.nmnh.si.edu/BIRDNET/documents/WNV&H5N1-FactSheet.pdf

# Avian Pox

(cutaneous or "dry" pox)

Vectors of this virus are blood feeding (hematophagous) arthropods such as fleas, several mosquito genera, and other biting insects.

Common Raven

*Photos courtesy of Dr. Victoria Bowes*

Van Riper et al proposed the following method for describing pox lesions:

- Light (1 lesion)
- Moderate (2 lesions)
- Heavy (3 or more or 1 large head lesion)

Lesions can coalesce causing partial blindness. Foot lesions can result in toe loss.

Rock Pigeon

*Bald Eagle photo courtesy of Tony Robinson*


Avian pox viruses target specific bird families.
It is very unlikely that crow pox would
infect eagles.
There is nothing wrong with this crow's eye.
The camera has captured the blue
nictitating membrane moving
across the eye.
Northwestern Crow
Photo courtesy of Tony Robinson

Skin lesions similar to avian pox virus are caused by:

- Nutritional deficiencies
- Mycotoxis
- *Papilloma* virus
- Scaly leg mites

For a definitive diagnosis, tissue is stained and viewed under a light or electron microscope.

Lesions excised with a sterile scalpel are either frozen at -20 C or preserved in 10% neutral-buffered formalin prior to histopathology assessment.

Northern Mockingbird

Quinta Mazatlan, McAllen, TX

This Rock Pigeon was found on a road. Massive internal bleeding confirmed that it died due to a vehicle collision, not a foot infection.

**DON'T ASSUME EVERY LESION IS AVIAN POX.**

The feet of this pigeon became infected after its feet were constricted by a red nylon rope.

Note that only two toes remain on one of the feet.

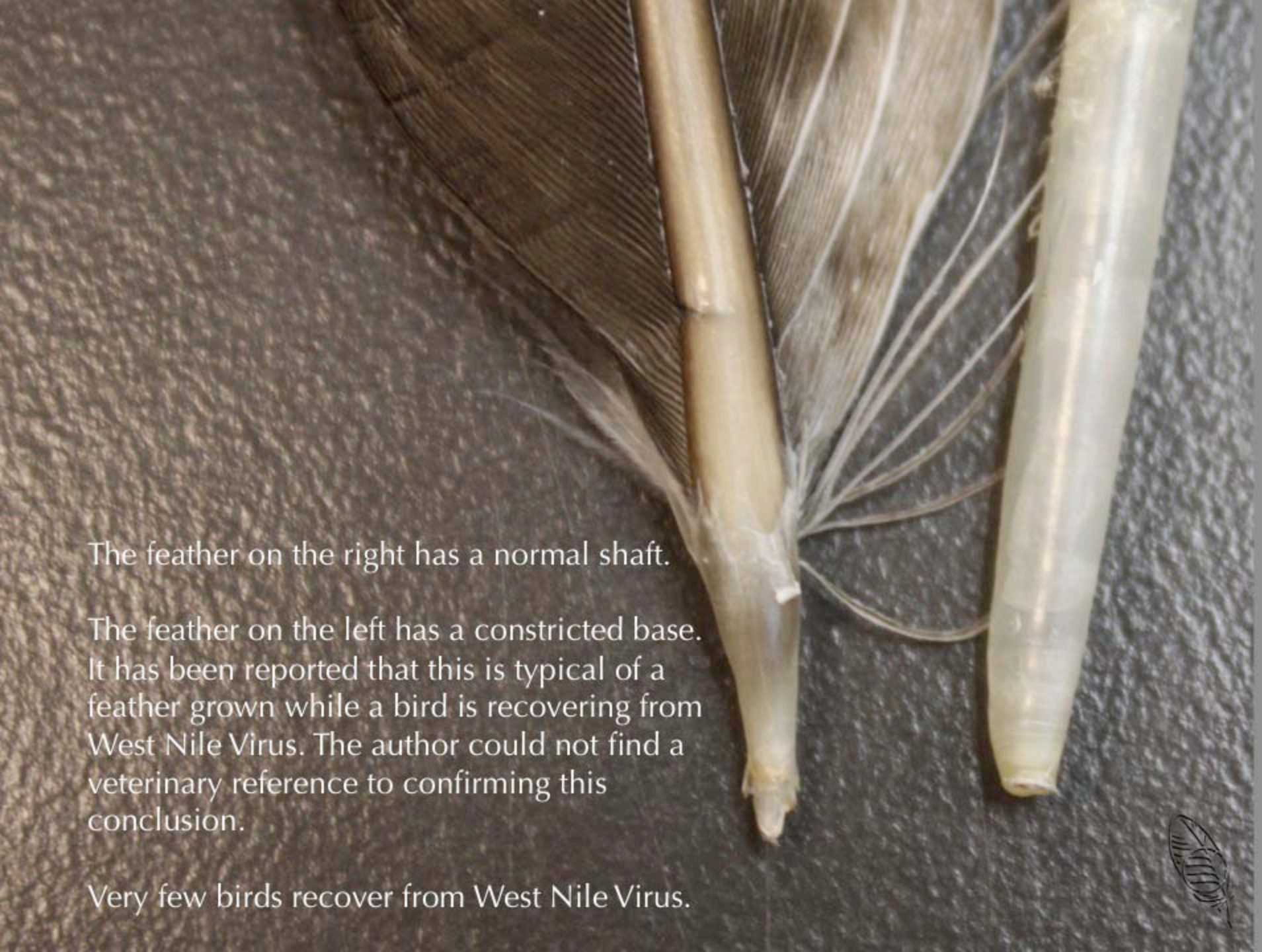

The feather on the right has a normal shaft.

The feather on the left has a constricted base. It has been reported that this is typical of a feather grown while a bird is recovering from West Nile Virus. The author could not find a veterinary reference to confirming this conclusion.

Very few birds recover from West Nile Virus.

Bumblefoot (ulcerative pododermatitis) is a bacterial infection *(Staphylococcus aureus) which* causes inflammation and sores.

| | |
|---|---|
| Mild: | Small reddened area or small shiny patch |
| Moderate: | Some penetration has occurred (as see above) |
| Severe: | Distortion of the contours of the foot and/or the toes |

Found in wild raptors but more common in domestic birds.

*Alwaslvetclinic.com via Wiki*

Check the soft palate of young birds with misshaped beaks.

*Trichomonas gallinae* (a protozoan) causes white or yellow ulceration in the soft palatte and may extend to the top of the digestive and/or respiratory tract. Chicks catch the disease when fed an infected bird or possibly from an infected parent. Adult birds rarely get *Trichomonas*.

This highly infections condition is called canker in pigeons and frounce in raptors.

*Trichomonas gallinae* is not known to infect humans.

Birds get internal and external cancers.

Nestling Barred Owl



Budgerigar


Gout is caused by elevated levels of uric acid in the blood.

Arthritic joint pain is caused by uric acid crystals deposited directly on bone or on tissue near a joint. This Trumpeter Swan has uric acid crystals on multiple organs and joints.

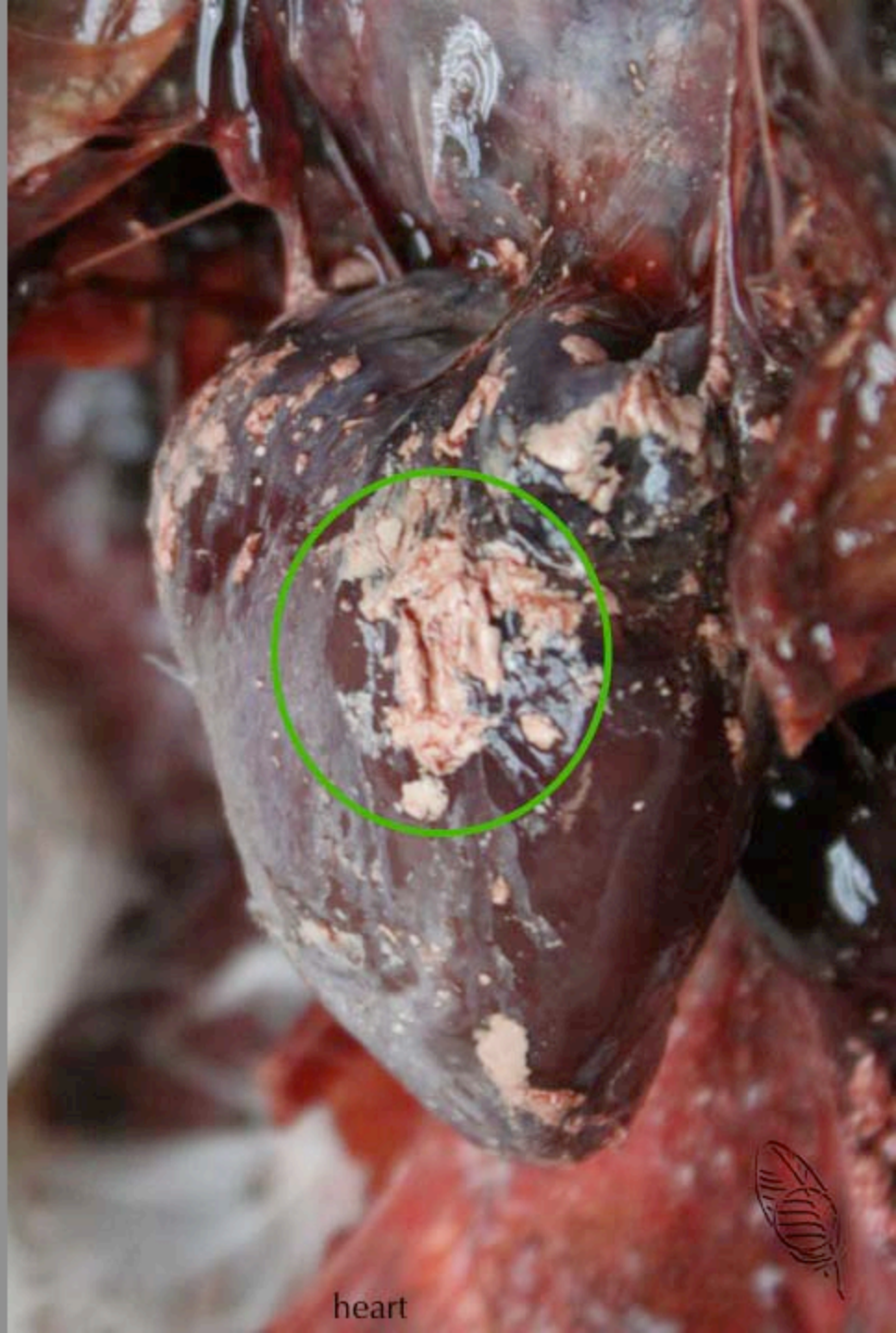


A health air sac is pseudo-transparent,
stretchy, and pink in colour.
Trumpeter Swan

In the early stages, *Aspergillus* fungus manifests itself as small nodes on the syrinx or air sacs of vegetarian, omnivorous, and carnivorous birds.

Trumpeter Swan

Snowy Owl

As the *Aspergillus* infection progresses, air sacs become thick, leathery, and often a yellow-green colour. Both these air sacs have been sliced open.

*Aspergillus* is a large genus of mold (fungus) found on decaying vegetation in damp environments. It is a natural part of the decay process.
Birds become infected when they aspirate the fungus spores.

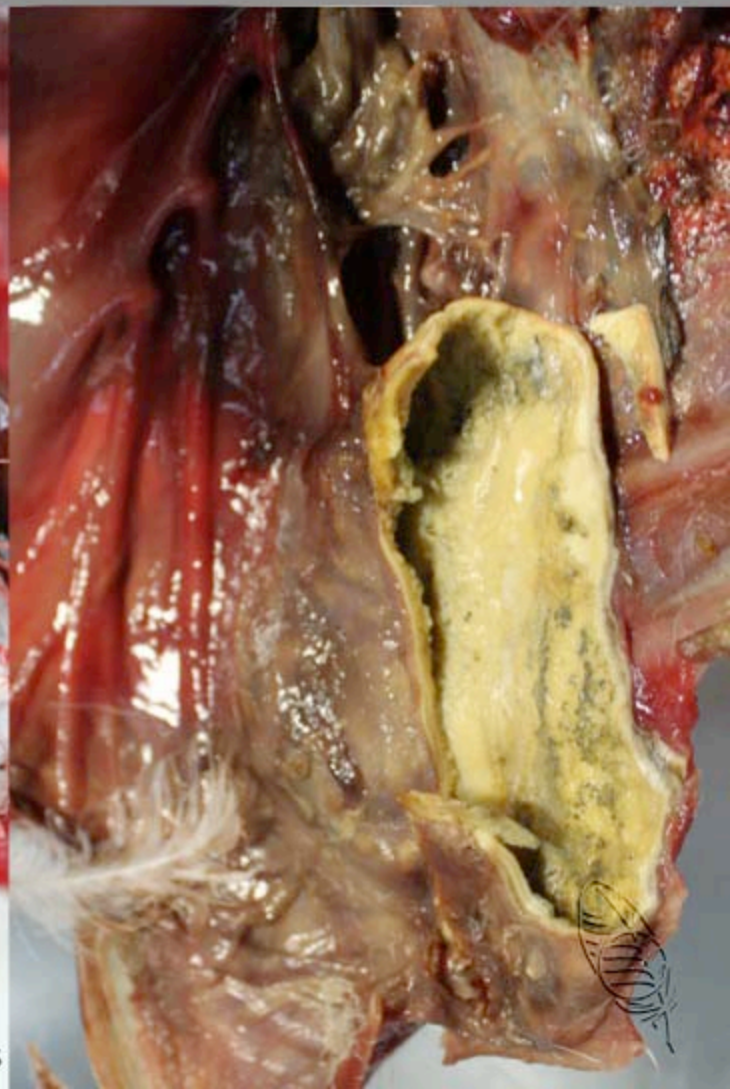

Trumpeter Swans

Birds with severe *Aspergillus* frequently exhibit nodes in the lungs.
Such birds have trouble breathing. Flying takes a huge effort.
Collisions with cars, wires, and electrocutions are often the manner of death.

# Avian Keratin Disorder (Long Bill) results in overgrowth of the rhamphotheca, the outer keratinized layer of the beak.

Beak deformities in birds are typically caused by:

- Infectious agents
- Parasites
- Genetic abnormalities
- Exposure to environmental contaminates
- Nutritional deficiencies

*Photo courtesy of J T Schopp*

Photo taken at University of Nebraska State Museum

*Photo courtesy of Kay & Robert Lookingbill ,Lake Jackson, TX*



Photo taken at TCWC, Texas A & M University

The cause of Avian Keratin Disorder is unknown. Diurnal raptors, hummingbirds, woodpeckers, and passerines get it.

The Falcon Research Group commissioned this N. John Schmitt drawing to promote discussion and encourage more accurate reporting of Avian Keratin Disorder.

BANANA-BILL

HOOK-BILL

NORMAL BILL

BROKEN-BILL

CROSS-BILL

SICKLE-BILL

*Illustration courtesy of Bud Anderson*
*Falcon Research Group - frg.org*


The tomia on the maxilla of these song sparrows is overgrown. It does not appear to have affected their health.
Photo taken at the Louisiana State University Museum of Natural Science
Photos of live bird, courtesy of Dr. Heather York, NE


This adult Indigo Bunting was migrating.
Despite the beak deformity,
her body condition was good.
She had visible fat reserves.
Photo courtesy of Mark Conway
Las Palomas WMA, Arroyo Colorado Unit, TX

No tests were done on this Brown Thrasher.
Scaly leg mites are suspected.
Check the whole bird for affected areas.


Photos taken at the
Louisiana State University Museum of
Natural Science

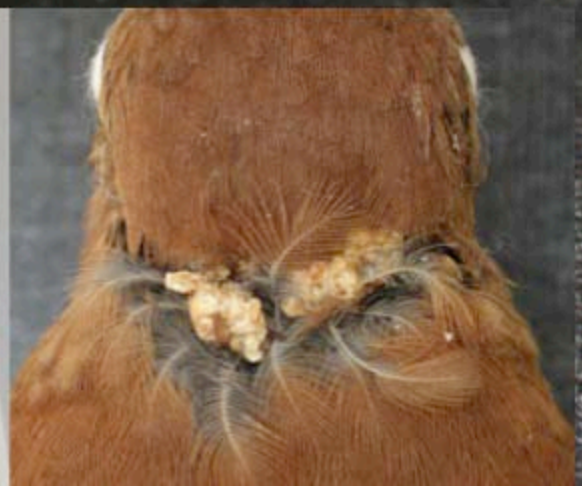

*Mite image photo courtesy of Dr. Heather C. Proctor*

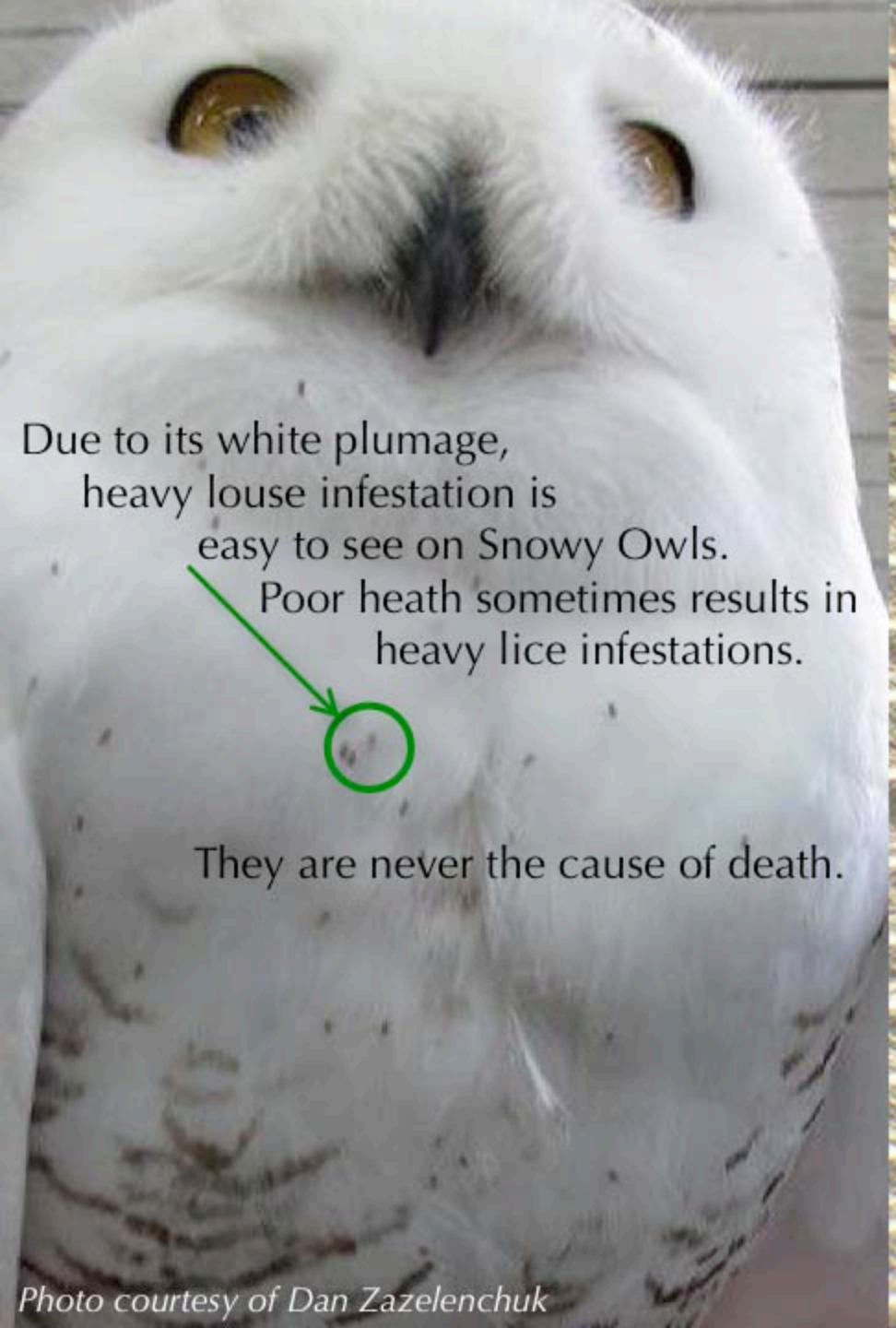


*Photo courtesy of Dan Zazelenchuk*

*Photo courtesy of Donald Griffiths*
*Spencer Entomology Collection*

*Photo taken from Federmilben.de*

For more complete information on ectoparasites, please go to:

## Part 9 - Washing Birds for Ectoparasites

This section describes and illustrates different types of ectoparasites.
It includes references and website links.

http://beatymuseum.ubc.ca/research/birds

# SUGGESTED READING FOR PART 13C & PART 13D


Guide to Raptor Remains: A Photographic Guide for Identifying the Remains of Selected Species of California Raptors, 2004. EDM International. 115pp.

Huffman, J.E. and J.R. Wallace. 2012. Wildlife Forensics: Methods and Applications. Wiley-Blackwell. 370pp.

Ornithological Council (2005, revised June 2010). West Nile Virus, Highly Pathogenic Avian Influenza H5N1, and other zoonotic diseases: what ornithologists and bird banders should know. 13pp. http://www.nmnh.si.edu/BIRDNET/documents/WNV&H5N1-FactSheet.pdf

Methane Burner Impacts on Raptors. 2013. Keeping company with Kestrels, Inc. and EDM International, Inc. 20pp.

Szabo, Ildiko. Preparing Bird Specimens: Part 9-Washing Birds for Ectoparasites. http://www.beatymuseum.ubc.ca/research/birds Accessed 2010.

Van Hemert, C., C. M. Handel, and D. M. O'Brien. 2012. Stable isotopes identify dietary changes associated with beak deformities in Black-capped Chickadees (*Poecile atricapillus*). The Auk 129:460-466.

Van Riper C III, Van Riper SG, Hansen WR: Epizootiogogy and effect of avian pox on Hawaiian forest birds. Auk 119:929-942.


*If you have photos, or additional information you wish to contribute to this topic please email:*

ildiko@zoology.ubc.ca

# IN MEMORIUM

## DR. REX KENNER

Former Curator of the Cowan Tetrapod Collection who encouraged me to begin this project.

At the 2012 Society for Wildlife Forensic Science Conference:

LUCY WEBSTER and NGAIO RICHARDS

independently informed me that this series was incomplete without a "Determining Cause of Death" presentation. Without their prodding and encouragement, I would not have tackled this topic.

If it was not for the tutelage of Dr. Victoria Bowes, Diagnostic Avian Pathologist for the British Columbia Ministry of Agriculture, and her toleration of my many questions while she was busy doing necropsies, I would still be struggling to compile this presentation.

Special thanks to Heather C. Proctor, Richard Harness, Joanne Mason, Laurie Wilson, Eve Szabo, Don Griffiths, Spencer Entomological Museum, Jack Evans, Bud Anderson, N. John Schmitt, Ellen Paul, and all the wildlife rehabilitators, bird banders, pathologist, museum curators and collection managers who have helped and encouraged me to complete this project. I take full responsibility for any remaining mistakes.

Without the technical assistance of Derek Tan, this project would never have gotten off the drawing board. Dr. Darren Irwin kindly suggested and made the arrangements for this series to be posted on the Beaty Biodiversity Museum website. A huge thank you to the staff and volunteers at the Cowan Tetrapod Collection for providing space and creating a terrific work environment.

Unless otherwise indicted, all pictures were taken by the author at the Cowan Tetrapod Collection, University of British Columbia Beaty Biodiversity Museum.

# OTHER PRESENTATIONS IN THIS SERIES

Introduction: The look of the bird & A few things to look for

- Part 1 - Spread wings, a good way to start
- Part 2 - Skinning your first bird
- Part 3 - Other skinning methods
- Part 4 - Stuffing your first bird
- Part 5 - Other stuffing and pinning methods & Bird parts
- Part 6 - Sexing birds using gonads (includes 2 quizzes with answer sheets)
- Part 7 - Determining skull pneumatization & Skeleton preparation
- Part 8 - DNA tissue sampling & Gut analysis
- Part 9 - Washing skins for ectoparasites & Drying washed skins
- Part 10 - Recording fat levels & Cleaning fatty or stinky skins
- Part 11 - Flat skins, shmoos, and other types of study skins
- Part 12 - Preserving eggs and shell fragments (in prep)
- Part 13 - Determining cause of death (in prep)
- Part 14 - Labelling: the most important step

To download another PowerPoint presentation in this series go to:
http://www.beatymuseum.ubc.ca/research/birds